

# Osteochondral Allograft Implantation Using the Smith–Peterson (Anterior) Approach for Chondral Lesions of the Femoral Head



Jeffrey W. Chen, B.A., Philip J. Rosinsky, M.D., Jacob Shapira, M.D., David R. Maldonado, M.D., Cynthia Kyin, B.A., Ajay C. Lall, M.D., M.S., and Benjamin G. Domb, M.D.

**Abstract:** Management of chondral lesions of the femoral head can be challenging. Previously described approaches include arthroscopic surgery for small lesions and open surgical dislocation for larger lesions. In 2001, Ganz popularized the trochanteric flip osteotomy for surgical dislocation, and this remains the workhorse for treatment of large chondral lesions. However, by using a Smith–Peterson (direct anterior) approach and a femoral head allograft, large lesions may be treated while avoiding both trochanteric osteotomy and donor-site morbidity. We present our technique using a Smith–Peterson approach and osteochondral implantation of fresh femoral head allograft for surgical treatment of a femoral head chondral lesion.

Chondral lesions of the femoral head are less common than lesions of the acetabulum; however, they are still commonly encountered in patients undergoing hip arthroscopy.<sup>1,2</sup> Chondral defects may be caused by trauma, femoroacetabular impingement, avascular necrosis, osteochondral lesion, or as a late sequela of Legg–Calve–Perthes disease. These lesions

can cause significant pain and mechanical symptoms, and may result in joint incongruity that can contribute to the development of secondary arthritis.<sup>3</sup>

Although first-line management is typically conservative with activity modification, anti-inflammatory medications, and physical therapy, failure of this regimen is an indication for surgical treatment. Surgical

*From the Vanderbilt University School of Medicine, Nashville, Tennessee, U.S.A. (J.W.C.); American Hip Institute Research Foundation, Des Plaines, Illinois, U.S.A. (P.J.R., J.S., D.R.M., C.K., A.C.L., B.G.D.); and American Hip Institute, Des Plaines, Illinois, U.S.A. (A.C.L., B.G.D.).*

*The authors report the following potential conflict of interest or source of funding: A.C.L. has received grants, personal fees, and nonfinancial support from Arthrex; nonfinancial support from Iroko; nonfinancial support from Medwest; nonfinancial support from Smith & Nephew; grants and nonfinancial support from Stryker; nonfinancial support from Vericel; nonfinancial support from Zimmer Biomet; and personal fees from Graymont Medical, outside the submitted work. D.M. is an editorial board member of the Journal of Arthroscopy and reports nonfinancial support from Arthrex, Stryker, Smith & Nephew, and Ossur, outside the submitted work. P.R. reports nonfinancial support from Arthrex, Stryker, Smith & Nephew, and Ossur, outside the submitted work. B.G.D. is the Medical Director of Hip Preservation at St. Alexius Medical Center; a board member for the American Hip Institute Research Foundation, AANA Learning Center Committee, the Journal of Hip Preservation Surgery, and the Journal of Arthroscopy; and has had ownership interests in the American Hip Institute, Hinsdale Orthopedic Associates, Hinsdale Orthopedic Imaging, SCD#3, North Shore Surgical Suites, and Munster Specialty Surgical Center. He reports grants and other from the American Orthopaedic Foundation, during the conduct of the study; personal fees from Adventist Hinsdale Hospital; personal fees and nonfinancial support from Amplitude; grants, personal fees, and nonfinancial support from Arthrex;*

*personal fees, and nonfinancial support from DJO Global; grants from the Kaufman Foundation; grants, personal fees, and nonfinancial support from Medacta; grants, personal fees, and nonfinancial support from Pacira Pharmaceuticals; grants, personal fees, and nonfinancial support from Stryker; grants from Breg; personal fees from Orthomerica; personal fees and nonfinancial support from Mako Surgical Corp; grants and nonfinancial support from Medwest; grants from ATI Physical Therapy; and grants, personal fees, and nonfinancial support from St. Alexius Medical Center, outside the submitted work. In addition, he has patent 8920497 – Method and instrumentation for acetabular labrum reconstruction with royalties paid to Arthrex; patent 8708941 – Adjustable multicomponent hip orthosis and royalties paid to Orthomerica and DJO Global; and patent 9737292 – Knotless suture anchors and methods of tissue repair with royalties paid to Arthrex. Full ICMJE author disclosure forms are available for this article online, as [supplementary material](#).*

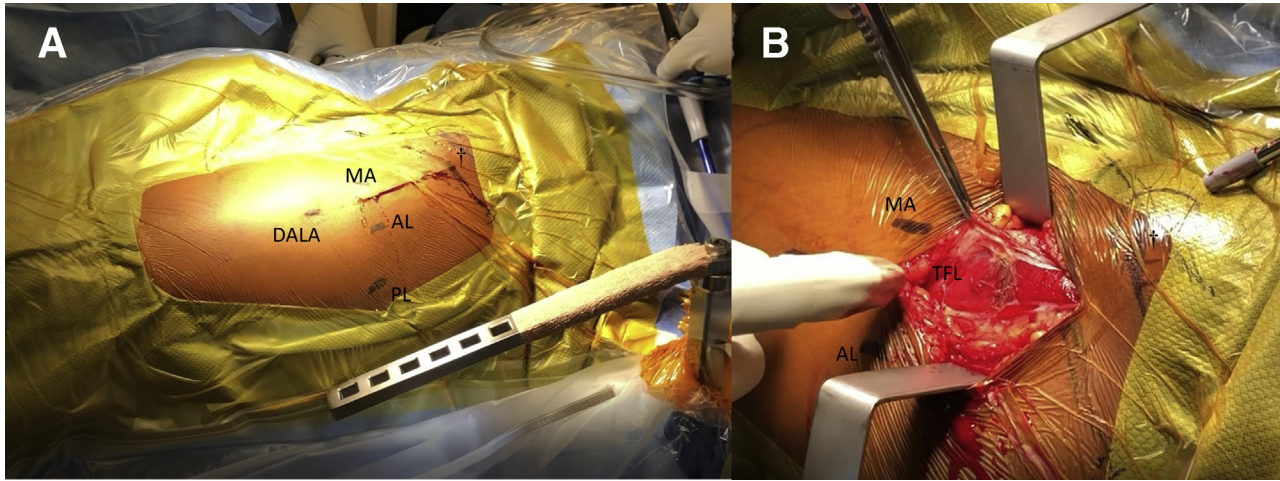
*Received June 25, 2019; accepted October 4, 2019.*

*Address correspondence to Dr. Benjamin G. Domb, American Hip Institute, 999 E Touhy Ave., Suite 450, Des Plaines, IL 60018. E-mail: [DrDomb@americanhipinstitute.org](mailto:DrDomb@americanhipinstitute.org)*

*© 2019 by the Arthroscopy Association of North America. Published by Elsevier. This is an open access article under the CC BY-NC-ND license (<http://creativecommons.org/licenses/by-nc-nd/4.0/>).*

*2212-6287/19810*

*<https://doi.org/10.1016/j.eats.2019.10.003>*



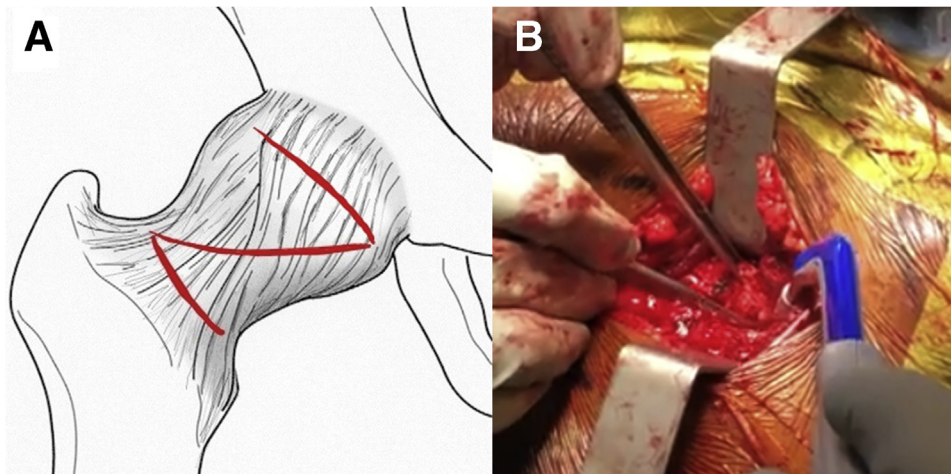
**Fig 1.** (A) The patient is positioned in the supine position and the left hip is draped in sterile fashion. The patient's head is to the right and feet to the left. The ASIS is marked (†). The 4 portals of a previously performed hip arthroscopy are identified, AL, MA, posterior lateral, and DALA. (B) The anterior approach is performed with an oblique 8-cm incision, extending from 2 cm distal and lateral to the ASIS and directed toward the fibular head. The fascia of the TFL muscle is split in line with the skin incision. Scar tissue from previous open procedures or arthroscopies may be encountered and may render identification of correct anatomical planes difficult. (AL, anterolateral; ASIS, anterior superior iliac spine; DALA, distal anterolateral accessory; MA, mid-anterior; TFL, tensor fascia lata.)

management options are dictated by lesion size and location. Surgical options include microfracture, autologous chondrocyte implantation, osteochondral autograft transfer (osteochondral autograft transplant system [OATS]; Arthrex, Naples, FL), osteochondral allograft implantation, femoral osteotomy, and arthroplasty.<sup>4</sup>

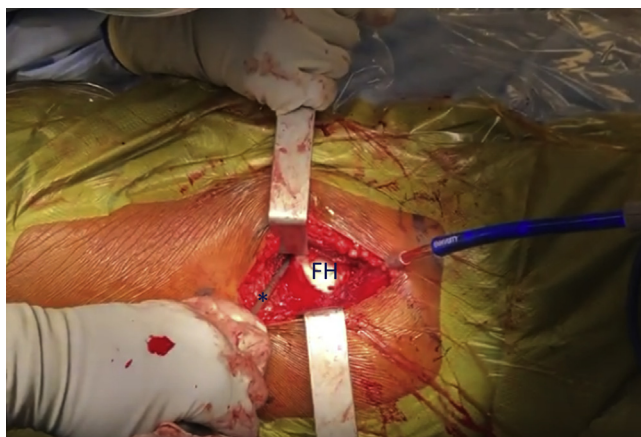
Viamont-Guerra et al.<sup>5</sup> reported on mosaicplasty of these types of lesions using an anterior approach and with osteochondral autograft plugs harvested from the non-weight-bearing region of the femoral head. The authors reported satisfactory outcomes as well as functional improvement, although they determined that this

method should be limited to lesions smaller than 2 cm<sup>2</sup>. One possible reason for inferior outcomes in patients with lesions larger than 2 cm<sup>2</sup> may be donor-site morbidity from autograft plugs harvested from the femoral head. Due to this concern, larger lesions may necessitate femoral head allograft for implantation.<sup>5</sup>

We have previously described our technique for allograft implantation through a trochanteric flip osteotomy for surgical hip dislocation.<sup>6</sup> Although this may be necessary for some lesions, especially more posterior lesions of the femoral head, we have since developed our Smith–Peterson (direct anterior) approach for mini-open surgical hip dislocation. This



**Fig 2.** (A) A schematic of a Z-capsulotomy from an anterior approach. The distal limb of the incision is made along the base of the femoral neck. A proximal limb of the incision is made extending along the acetabular rim. A longitudinal incision in the capsule completes the capsulotomy and the capsule is retracted. The incision lines are shown in red. (B) An intraoperative image of the Z-capsulotomy performed.



**Fig 3.** A bone hook (\*) is used to guide the FH out of the socket as an assistant at the foot of the patient simultaneously and slowly externally rotates the limb to 45°. Adequate distraction is maintained throughout the dislocation to avoid damage of the labrum by the FH during rotation. After dislocation, the limb is externally rotated further to 130° and then taken off traction and brought into extension and adduction to achieve anterior exposure of the FH through the surgical incision. (FH, femoral head.)

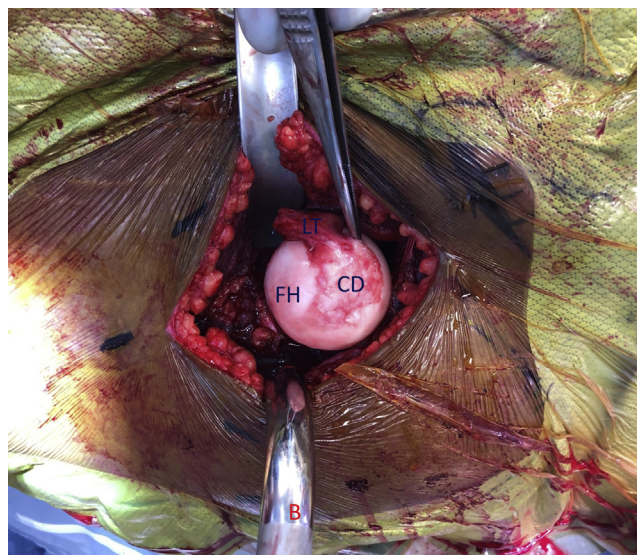approach is especially useful in cases in which the femoral head allograft is performed as a secondary procedure subsequent to an earlier arthroscopic procedure, in which the labral pathologies were already addressed.

## Surgical Technique

### Patient Positioning and Approach

General anesthesia and antibiotic prophylaxis are administered. The patient is positioned in the supine position on a Hana table (Mizuho, Union City, CA) with a well-padded perineal post and foot restraints. The patient is draped in sterile fashion with anatomical landmarks marked. Any prior incisions should also be marked. An oblique 8-cm incision is performed, extending from 2 cm distal and lateral to the anterior superior iliac spine and directed toward the fibular head. The fascia of the tensor fascia lata (TFL) muscle is identified and split in line with the skin incision, allowing the TFL to be retracted laterally while the medial fascia of the TFL and the sartorius are retracted medially (Fig 1 A and B).

At this point, scar tissue from previous open procedures or arthroscopies may be encountered and may render identification of correct anatomical planes difficult. Thus, care must be taken to avoid inadvertent injuries to the medial neurovascular bundle. Numerous blood vessels and branches of the lateral femoral circumflex artery (LFCA) overlay the deep fascia of the TFL and should be preserved. The LFCA has a smaller contribution to femoral head and neck blood supply



**Fig 4.** Image of the anteriorly exposed left FH. The patient's head is to the right and feet to the left. A 25-mm × 25-mm FH defect (CD) was identified. The LT remains attached medially to the head. The incision is retracted medially, and a femoral bump (B) is used to elevate the femoral head through the incision. (FH, femoral head; LT, ligamentum teres stump.)

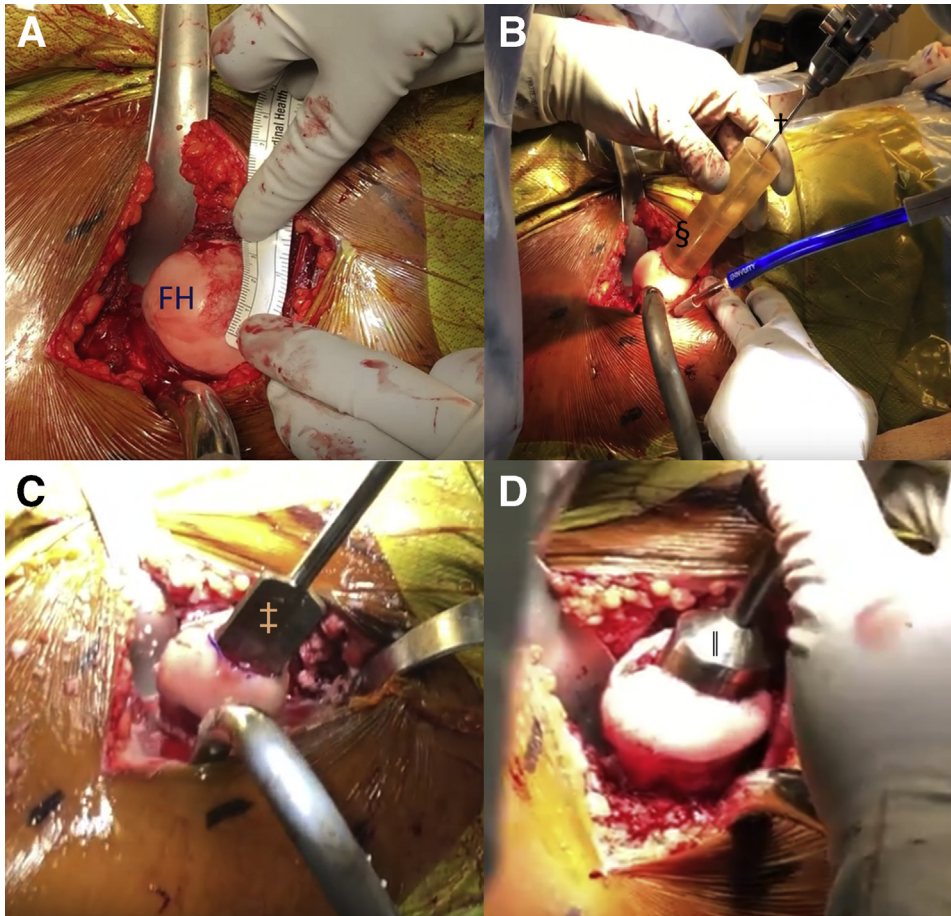
relative to the medial femoral circumflex artery (MFCA). However, it still contributes significantly to the inferior femoral neck as well as to the greater trochanter and should be protected.<sup>7</sup>

After the deep fascia of the TFL is incised, the precapsular fat is readily visible. The gluteus medius is retracted superolaterally while the rectus femoris is retracted medially to expose the capsule in its entirety. A Z-capsulotomy is performed with the proximal limb extending along the acetabular rim and the distal limb extending along the base of the femoral neck, taking care to preserve the retinacular vessels (Fig 2 A and B). An oblique longitudinal incision in the capsule completes the capsulotomy, and the capsule is retracted.

### Surgical Dislocation (With Video Illustration)

After the capsule is retracted and the joint is visible, the limb is placed in traction. If the labrum is well functioning, a break of the suction seal can be audible as the femoral head leaves the acetabular socket (Video 1). A bone hook is then used to guide the femoral head out of the socket as the assistant simultaneously and slowly externally rotates the limb to 45°. Adequate distraction should be maintained during dislocation to avoid damaging the labrum. Once the joint is dislocated, the limb is taken off traction, externally rotated to 130° and then brought into extension and adduction (Fig 3).

A femoral elevator is then used to expose the femoral head through the surgical site and to enhance

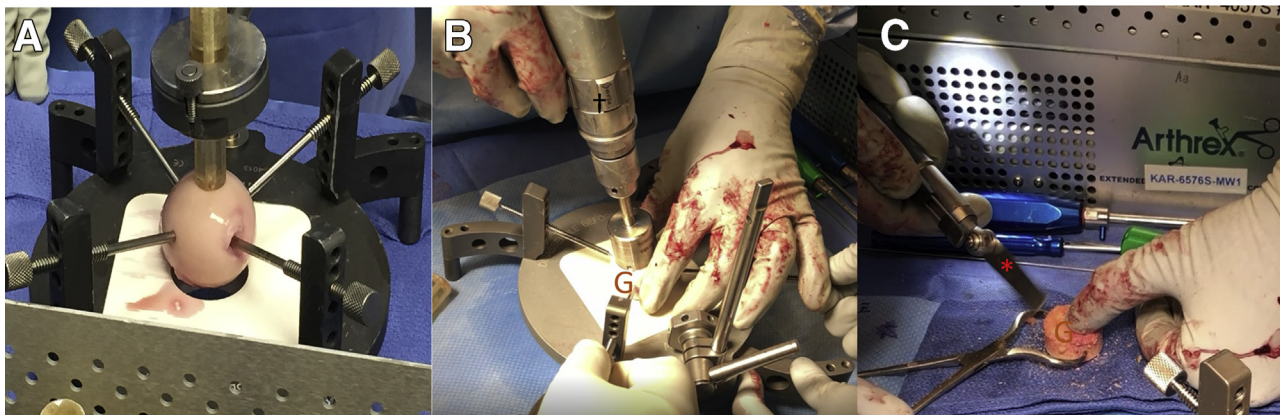


**Fig 5.** (A) After resection of unstable cartilage from the FH, the borders of the lesion are identified and measured. (B) The Osteochondral Autograft Transplant System (OATS; Arthrex, Naples, FL) cannulated sizers (§) are used to evaluate the defect size and the required corresponding graft. An appropriate sizer is placed perpendicularly over the lesion. A guidewire (†) is drilled through the cannulated sizer into the femoral head. (C) The calibrated OATS counterbore is guided to the defect site by the previously inserted drill-tip guide pin. The counterbore (‡) is drilled into the lesion to a depth of 10-15 mm, until bleeding subchondral bone is reached. (D) After completion of drilling at the recipient site, an appropriately sized dilator (||) is introduced into the lesion to achieve a dilation of 0.5 mm. (FH, femoral head.)

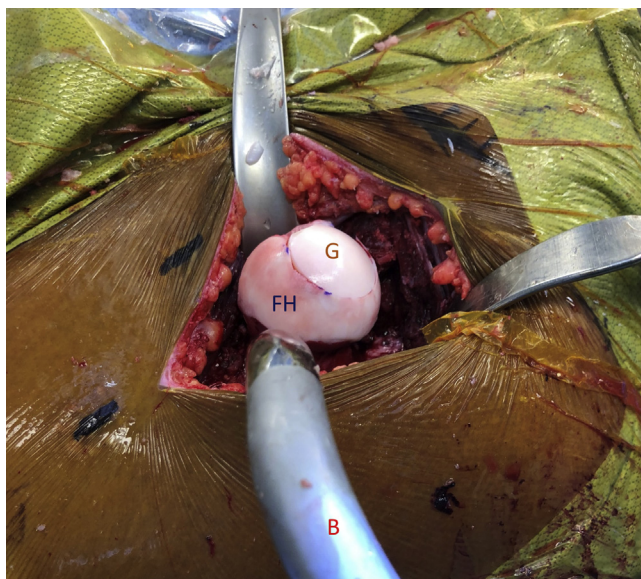visualization of the femoral head defect. Remnants of the ligamentum teres will likely need to be excised at this time (Fig 4). Caution should be taken to avoid scuffing the femoral head with any retractors throughout the case.

### Chondral Lesion Preparation

Any unstable cartilage is resected. The borders of the lesion are identified and measured in their entirety. The Osteochondral Autograft Transplant System (OATS; Arthrex) is then used to size, harvest, and implant the



**Fig 6.** (A) Preparation of fresh femoral head allograft. The fresh femoral head allograft secured in the Arthrex Allograft Osteochondral Autograft Transplant System (OATS) Workstation, and perpendicular alignment is confirmed with the OATS sizer. (B) After measuring the lesion defect with the appropriate sizer, the corresponding drill bit (†) is used to harvest the fresh femoral head graft (G). (B) An osteotome (\*) is used to round the edge of the graft and achieve fine changes to accommodate variations in lesion site depth.



**Fig 7.** Image of the implanted graft in the femoral head of the left hip. The patient's head is to the right and feet to the left. The fresh femoral head allograft (G) has been press-fit into place and sits firm and flush against the curvature of the native head (FH). The incision is retracted medially and laterally, and a femoral bump (B) is used to elevate the femur, exposing the head. (FH, femoral head.)

graft. The OATS system includes cannulated sizers to evaluate the defect size and the required corresponding graft. The appropriate sizer is placed perpendicularly over the lesion. A drill tip is drilled through the cannulated sizer into the femoral head and the sizer is removed. The calibrated OATS recipient counterbore is placed over the drill-tip guide pin and drilled into the lesion to a depth of 10 to 15 mm, until bleeding subchondral bone is reached. After completion of drilling the recipient site, an appropriately sized dilator is introduced into the lesion to achieve a dilation of 0.5 mm. A pinpoint ruler is used to record depth measurements at the 12-, 3-, 6-, and 9-o'clock positions of the lesion (Fig 5, A-D).

### Femoral Head Allograft Preparation

The donor femoral head allograft is secured in the Arthrex Allograft OATS Workstation, and perpendicular alignment is confirmed with the OATS sizer. The allograft OATS donor harvester with a collared guide

pin is attached to the drill, passed into the proximal graft housing, and rested on the graft's surface. The harvester is subsequently drilled to a depth of 15 mm and then removed. The graft is cut based on the dimensions of the recipient site and the edges of the graft are beveled to ensure easy implantation. Appropriate margins for the graft core are confirmed to ensure a snug press-fit and to prevent countersinking (Fig 6 A-C).

### Graft Implantation

The OATS dilator is introduced once more, and the recipient site is copiously lavaged. A small amount of demineralized bone matrix (StimuBlast DBM; Arthrex) can be used to ensure adequate filling of the recipient site and provide an osteoconductive and osteoinductive medium to the site. The allograft is then press-fitted, ensuring that the cartilage of the graft sits flush with the surrounding cartilage (Fig 7). Prominent edges may be lightly smoothed for congruity of the articular surface.

### Hip Reduction and Closure

The limb is placed back on traction and the limb is internally rotated by an assistant. Traction is then slowly released to allow the femoral head to reenter the joint. A visual inspection of the femoral head and labrum is conducted to ensure proper reduction and condition of the labrum.

The pearls and pitfalls of this technique are summarized in Table 1.

### Postoperative Rehabilitation

The patient is placed in a brace for 6 weeks to protect the hip and limit abduction and rotation. Gentle passive range-of-motion exercise is initiated during the first week, under the supervision of a physiotherapist. The patient remains limited to 20 lb of flat-foot partial weight bearing during the first 6 weeks. Active hip flexion is not allowed until week 6, after which weight bearing is gradually increased. Full weight bearing is allowed at 8 weeks after surgery.

## Discussion

We present our mini-open technique for surgical dislocation of the hip using a Smith–Peterson (anterior)

**Table 1.** Pearls and Pitfalls

Pearls	Pitfalls
<ul style="list-style-type: none"> <li>• During the surgical approach, perform careful dissection, especially in cases with previous surgery and scar formation.</li> <li>• Ensure accurate size matching of recipient and donor sites and use demineralized bone matrix as adjuvant filler.</li> <li>• During capsulotomy of the proximal limb along the acetabular rim, an inside-out technique should be used to avoid damage to the labrum.</li> </ul>	<ul style="list-style-type: none"> <li>• Femoral head damage from aberrant retractor placement.</li> <li>• Retinacular vessel and other vascular damage from excessive use of electrocautery.</li> <li>• Labral damage from inadequate distraction during dislocation.</li> <li>• Incongruence of the articular surface from countersinking of the allograft.</li> </ul>

**Table 2.** Advantages and Disadvantages for Anterior Approach Versus Trochanteric Flip Osteotomy

Advantages	Disadvantage
<ul style="list-style-type: none"> <li>• Intermuscular plane, with minimal damage to the muscles.</li> <li>• Avoidance of the MFCA, the major blood supply to the femoral head and neck.</li> <li>• Avoidance of a trochanteric osteotomy with possible non- or malunion of osteotomy.</li> <li>• Avoidance of hardware for osteotomy fixation or need for hardware removal.</li> </ul>	<ul style="list-style-type: none"> <li>• Encountering scar tissue in cases of previous surgery via anterior approach or prior arthroscopy.</li> <li>• Limited access to posteroinferior quadrant of femoral head.</li> <li>• Limited access to acetabulum and labrum.</li> </ul>

MFCA, medial femoral circumflex artery.

approach for femoral head osteochondral allograft implantation. This can be used to treat chondral lesions located almost circumferentially around the femoral head.

Although chondral lesions of the femoral head are uncommon, they remain an important cause of hip pain and will inevitably be encountered in a sports medicine practice performing hip arthroscopy. In patients undergoing hip arthroscopy, the impact of femoral head lesions has been shown to be detrimental, with lower outcome scores and greater rates of conversion to total hip arthroplasty.<sup>2,8</sup> Current treatment options are limited and are technically demanding even for an experienced surgeon. Arthroscopic osteochondral transplantation had been described for chondral lesions at the femoral head, but its use is limited to smaller lesions along the anterosuperior and anterolateral aspects of the femoral head, due to visualization constraints.<sup>9-11</sup> Previously, we described our technique via a trochanteric flip osteotomy, which may still be indicated in lesions of the posteroinferior quadrant or in cases in which concomitant treatment of the labrum is required.

There are a number of advantages for using the anterior approach when compared with the trochanteric flip osteotomy. First, complications associated with a trochanteric osteotomy such as potential malunion or nonunion are avoided. These have been shown to occur at significant rates and may lead to impairment of hip abductor function. In addition, the need for osteotomy fixation by hardware may lead to lateral hip pain and irritation and may require a subsequent operation for hardware removal.<sup>12,13</sup>

Second, by using the Smith–Peterson approach, the MFCA, which serves as the primary vascular supply to the femoral head and neck, is not put at risk. Previous reports have measured femoral head perfusion following trochanteric flip osteotomy and have shown this procedure to be safe, with very low rates of avascular necrosis.<sup>14,15</sup> However, the MFCA remains potentially vulnerable during trochanteric osteotomy, and in rare cases it may be injured.<sup>16</sup> Conversely, during the Smith–Peterson approach, the LFCA is encountered after retraction of the TFL laterally.

Although this vessel provides only an ancillary vascular supply to the femoral head and neck, it does contribute to the blood supply of the greater trochanter, and care should be taken to preserve its branches. In addition, the retinacular vessels are encountered during capsulotomy, and these should be preserved as well.<sup>7</sup>

Lastly, the Smith–Peterson approach is considered a muscle-sparing approach, potentially leading to less muscular injury during surgery, as well as enabling a faster recovery from surgery. Although patients after osteochondral allograft implantation are placed on weight-bearing restrictions for at least 6 weeks following surgery, this still provides a potential benefit in the rehabilitation process. The overall advantages and disadvantages of the anterior approach relative to the trochanteric flip osteotomy approach are summarized in Table 2.

The indications for the described technique are grade III and IV chondral lesions according to the International Cartilage Repair Society classification located almost circumferentially around the femoral head, excluding lesions of the posteroinferior quadrant. Fresh-stored osteochondral allograft transplantation through a Smith–Peterson (direct anterior) approach is a feasible alternative for such lesions. The avoidance of a trochanteric osteotomy with its associated morbidity, as well as absence of donor-site morbidity, may allow for faster rehabilitation and earlier return to function.

## References

1. Fontana A, Mancini D, Gironi A, Acerbi A. Hip Chondral lesions: Arthroscopic evaluation. *Hip Int* 2016;26:S17-S22 (suppl 1).
2. Ashberg L, Close MR, Perets I, et al. Do femoral head chondral lesions predict a poor outcome in hip arthroscopy patients? A matched control study with minimum 5-year follow-up. *Arthroscopy* 2019;35:419-431.
3. Johnson JD, Desy NM, Sierra RJ. Ipsilateral femoral head chondral transfers for chondral defects of the femoral head. *J Hip Preserv Surg* 2017;4:231-239.
4. El Bitar YF, Lindner D, Jackson TJ, Domb BG. Joint-preserving surgical options for management of chondral injuries of the hip. *J Am Acad Orthop Surg* 2014;22:46-56.
5. Viamont-Guerra M-R, Bonin N, May O, Le Viguelloux A, Saffarini M, Laude F. Promising outcomes of hip

- mosaicplasty by minimally invasive anterior approach using chondral autografts from the ipsilateral femoral head [published online February 28, 2019]. *Knee Surg Sports Traumatol Arthrosc*. doi: 10.1007/s00167-019-05442-1.
6. Maldonado DR, Mu BH, Chen AW, et al. Fresh femoral head chondral allograft transplantation for treating osteochondritis dissecans of the femoral head. *Arthrosc Tech* 2018;7:e331-e335.
  7. Seeley MA, Georgiadis AG, Sankar WN. Hip vascularity: A review of the anatomy and clinical implications. *J Am Acad Orthop Surg* 2016;24:515-526.
  8. Redmond JM, Gupta A, Dunne K, Humayun A, Yuen LC, Domb BG. What factors predict conversion to THA after arthroscopy? *Clin Orthop Relat Res* 2017;475:2538-2545.
  9. Kubo T, Utsunomiya H, Watanuki M, Hayashi H, Sakai A, Uchida S. Hip arthroscopic chondral autologous transplantation for treating osteochondritis dissecans of the femoral head. *Arthrosc Tech* 2015;4:e675-e680.
  10. Girard J, Roumazielle T, Sakr M, Migaud H. Chondral mosaicplasty of the femoral head. *Hip Int* 2011;21:542-548.
  11. Uchida S, Utsunomiya H, Honda E, et al. Arthroscopic chondral autologous transplantation for the treatment of osteochondritis dissecans of the femoral head. *SICOT J* 2017;3:18.
  12. Sink EL, Beaulé PE, Sucato D, et al. Multicenter study of complications following surgical dislocation of the hip. *J Bone Joint Surg Am* 2011;93:1132-1136.
  13. Beaulé PE, Le Duff MJ, Zaragoza E. Quality of life following femoral head-neck osteochondroplasty for femoroacetabular impingement. *J Bone Joint Surg Am* 2007;89:773-779.
  14. Ganz R, Gill TJ, Gautier E, Ganz K, Krügel N, Berlemann U. Surgical dislocation of the adult hip a technique with full access to the femoral head and acetabulum without the risk of avascular necrosis. *J Bone Joint Surg Br* 2001;83:1119-1124.
  15. Lazaro LE, Sculco PK, Pardee NC, et al. Assessment of femoral head and head-neck junction perfusion following surgical hip dislocation using gadolinium-enhanced magnetic resonance imaging: A cadaveric study. *J Bone Joint Surg Am* 2013;95:e1821-e1828.
  16. Tibor LM, Sink EL. Pros and cons of surgical hip dislocation for the treatment of femoroacetabular impingement. *J Pediatr Orthop* 2013;33:S131-S136 (suppl 1).